



Anterior Segment Dysgenesis: The Oral Involvement-Case Report

[PP: 01-06]

Dr. Pavanalakshmi G.P MDS

Senior Lecturer

Department of Pedodontics and Preventive Dentistry
Vydehi Institute of Dental Sciences and Research Centre
Bengaluru, Karnataka, **India****Dr. Jaya Naidu MDS**

Professor

Department of Pedodontics and Preventive Dentistry
Vydehi Institute of Dental Sciences and Research Centre
Bengaluru, Karnataka, **India****Dr. Pavan B Tambakad MDS**

Professor and Head of the Department

Department of Pedodontics and Preventive Dentistry
Vydehi Institute of Dental Sciences and Research Centre
Bengaluru, Karnataka, **India**

ARTICLE INFO

Article History

The paper received on:

15/01/2015

Reviewed on:

02/02/2015

Accepted on:

23/02/2015

ABSTRACT

Anterior segment dysgenesis is a spectrum of ocular malformations of the anterior chamber of the eye and iris. It is classified into various subtypes. We report a case of a four year old boy with overlapping features of the subtypes Axenfeld-Reiger syndrome and Peters' anomaly with significant extra-oral and oral findings which helped the ophthalmologists to diagnose this rare condition.

Keywords: Anterior segment, dysgenesis, ocular malformations, Axenfeld-Reiger syndrome, Peters' anomaly

Cite this article as:

Pavanalakshmi,G. P., Naidu, J., & Tambakad, P.B. (2015). Anterior Segment Dysgenesis: The Oral Involvement-Case Report. *Case Reports in Odontology* 2(1), 01-06. Retrieved from www.casereportsinodontology.org



1. Introduction

Anterior segment dysgenesis (ASD) was first described by Hittner H.M., Kretzer F.L., Antoszyk J.H., Ferrell R.E., & Mehta R.S. (1982).⁵ ASD is the aberrant development of the tissues of the anterior chamber of the eye which are the ciliary body, lens, iris and cornea. It is associated with increased risk of glaucoma and corneal opacity. Sowden J.C. (2007)¹⁰, classified ASD based on the clinical phenotypes into:

- Aniridia
- Axenfeld anomaly
- Reiger anomaly
- Iridogoniodysgenesis
- Peters' anomaly
- Posterior embryotoxon

The etiology of ASD is thought to be the abnormalities in the migration and or differentiation of the neural crest derived mesenchymal cells. These cells differentiate into the various cell types that appear to be involved in the ocular, dental and systemic manifestations of this condition as discussed by Kuper C and Kaiser-Kuper M.I. (1978).⁷ It results from mutations in several transcription factors like- PITX2, PITX3, PAX6, FOXC1 according to Alward W. L. M. (2000).¹ Cases are most often recognized in infancy or childhood because of abnormal appearance of the anterior segment. In some infants the concerns could be tearing photophobia, and corneal clouding which are the signs of infantile glaucoma. Other patients would present with visual loss. Dental and craniofacial involvement are significant according to Waring G.O. 3rd, Rodrigues M. M. & Laibson P.R. (1975).¹¹

2. Case Report

A four year old male patient, who complained of decreased vision and with provisional diagnosis of Rieger anomaly, was referred to the Department of

Pedodontics and Preventive dentistry for dental evaluation. The child was born on term from a non-consanguineous marriage. There was no positive family history. The developmental milestones were attained normally.

On Examination

Ocular abnormalities:

microphthalmos, microcornea, strabismus, bilateral jerky nystagmus, alternating esotropia, corectopia, iridocorneal adhesions with the left eye, iris showed patches of atrophy, bilateral cataracts and partial vision loss with respect to both the eyes (Figure 1). The intraocular pressure was within normal limits.

Extra oral examination:

The child presented with Dolichocephaly, microcephaly, preauricular tags with respect to left ear (Figure 2), underdevelopment of the left tragus and a beak shaped nose (Figure 3).

Intraoral Examination:

- Missing teeth:
 - In Deciduous dentition: 72,73,82,83 (Figure 4)
 - In Permanent dentition (revealed on Orthopantomogram): 31, 32, 33, 34, 41, 42, 43, 44 (Figure 5)
 - Confirmation of hypodontia
- Decayed teeth: 51, 61, 62 (grossly decayed), 54, 55, 64, 65, 74, 75, 84, 85 (Figure 6)
- Ankyloglossia (Figure 4)
- High arched palate.

Further systemic investigations were carried out. Blood investigations were within normal limits. Echo revealed Patent ductus arteriosus, left to right shunt.

Based on the ocular, dental and systemic involvement, the child was diagnosed having both features of Axenfeld-Reiger syndrome and Peters' anomaly.

3. Discussion

Cite this article as: Pavanalakshmi, G. P., Naidu, J., & Tambakad, P.B. (2015). Anterior Segment Dysgenesis: The Oral Involvement-Case Report. *Case Reports in Odontology* 2(1), 01-06. Retrieved from www.casereportsinodontolog.org



The presenting case showed overlapping features of Axenfeld-Reiger syndrome and Peters' anomaly. Axenfeld-Reiger syndrome (ARS) is categorized under the group of anterior segment dysgenesis. This disorder is seen in approximately 1 in 200,000 live births. It is inherited as an autosomal dominant trait with equal gender predilection and has a wide spectrum of variability in clinical expression as discussed by Waring G. O. 3rd, Rodrigues, M. M., Laibson, P. R. (1975).¹¹ In 1920, Axenfeld described posterior embryotoxon and adherent iris strands, and in 1935, Reiger described congenital iris abnormalities including iris hypoplasia, corectopia and poly cornea associated with other systemic findings like dental, facial anomalies. The combination of the Axenfeld anomaly and Reiger syndrome is collectively known as Axenfeld-Reiger syndrome as discussed by Shields M. B., Buckley E, Klintworth G.K., & Thresher R.(1985).⁹ The present case showed esotropia, corectopia, iris hypoplasia which are features of ARS. Along with these ocular features, the patient also presented with iridocorneal adhesions with the left eye, iris showed patches of atrophy, bilateral cataracts which are the features of Peters' anomaly. Peters' anomaly is one of the sub category of anterior segment dysgenesis characterized by abnormal cleavage of the anterior chamber of the eye which could include the central or the entire cornea. This anomaly occurs sporadically or as autosomal recessive but rarely as autosomal dominant, as according to Giri G (nd).⁴

Dental findings in ARS vary from microdontia to complete anodontia. Missing lateral mandibular incisors are described to be the most common feature, which was also seen in the above mentioned case report. According to Axenfeld T.H. (1920),

maxillary hypoplasia can also be seen in these patients.³ Jena A.K and Kharbanda O. P. (2005) observed that patients with ARS also presented with short rooted teeth, dilacerated roots, and hyperplastic freni.⁶ Malocclusions like crossbite, openbite, and moderate to severe crowding are not uncommon.⁶ Our patient presented with hypodontia affecting both deciduous and permanent dentition, high arched palate which are seen ARS, with this he also presented with ankyloglossia which is a unique finding.

Systemic findings include ear abnormalities, hearing loss. In our case the patient presented with preauricular tags with the left ear. Pituitary and cardiac abnormalities, short status, hypospadias and limb defects are seen with ARS. Our patient presented with Patent ductus arteriosus.

The PITX2 association:

It is the Paired liked homeodomain transcription factor 2 which plays a vital role in the development of the eye, teeth, asymmetrical development of the heart, lungs etc. The mutation of this protein is associated with ARS. PITX2 is expressed throughout the tooth development process. It is the earliest known transcription factor which expresses selectively in the oral ectoderm. Amendt B. A. (2000) stated that the tooth abnormalities seen in ARS patients may vary, with all of the aforementioned clinical findings or only one.² The dental findings are highly penetrant; only about 9% of patients with PITX2 mutations display isolated ocular defects as given by Semina E.V. et al.(1996).⁸

Management:

The complication of ARS and Peters' anomaly is the development of glaucoma and subsequent vision loss. Glaucoma in infancy presents as photophobia, tearing and corneal clouding with corneal enlargement.



At this point if diagnosed, surgical intervention can prevent vision loss. When glaucoma is diagnosed in early adulthood, the disease is already in the advanced stage. The best scenario at this point is to screen the sibling or the offspring of the patient for ASD, so that the disease is diagnosed at an early stage and prevented from vision loss.

Dental Management:

The aim of dental rehabilitation is to improve both aesthetics and function. The dental defects associated usually require orthodontic and prosthodontic treatment as a result of malocclusion associated with multiple missing teeth. Dental implants is the most likely treatment option for patients with hypodontia.

4. Conclusion

Anterior segment dysgenesis is diagnosed based on the clinical findings. The signs are detectable since birth. The dentist plays a vital role in diagnosing the condition there by preventing the complication of vision loss. The rarity, low incidence, high morbidity and potential complications call for a through recording and maintaining a data base. This could provide an insight into the pathogenesis so that genetic counselling is necessitated and early and prompt treatment could be available for this debilitating condition.

References

- 1. Alward, W.L.M. (2000).** Perspective: Axenfeld-Rieger Syndrome in the Age of Molecular Genetics. *Am. J. Ophthalmol.*, 130, 107-115.
- 2. Amendt B.A. (2005).** The role of PITX2 in tooth development. *The molecular mechanisms of Axenfeld Rieger syndrome Medical Intelligence Unit*, 81-92.
- 3. Axenfeld T.H. (1920).** Embryotoxon cornea posterius. *Klin Monatsbl Augenheilkd*, 65, 381-382.
- 4. Giri.G. (nd).** Peters' anomaly. *Medscape*. Retrieved from <http://emedicine.medscape.com/article/1200372/overview#a0101>.
- 5. Hittner H.M., Kretzer F.L., Antoszyk J.H., Ferrell R.E., Mehta R.S. (1982).** Variable expressivity of autosomal dominant anterior segment mesenchymal dysgenesis in six generations. *Am J Ophthalmol*, 93, 57-70.
- 6. Jena A.K., Kharbanda O.P. (2005).** Axenfeld-Rieger syndrome: Report on dental and craniofacial findings. *J Clin Pediatr Dent*, 30(1), 83-88.
- 7. Kupfer C, Kaiser – Kupfer M.I. (1978).** New hypothesis of developmental anomalies of the anterior chamber associated with glaucoma. *Trans Ophthalmol Soc UK*, 98(2), 213-215.
- 8. Semina E.V., Datson N.A., Leysens N.J., Zabel B.U., Carey J.C., Bell G.I., Murray, J.C. (1996).** Exclusion of epidermal growth factor and high resolution physical mapping across the Reiger syndrome locus. *Am J Hum Genet*; 59(6), 1288-1296.
- 9. Shields M.B., Buckley E, Klintworth G.K., Thresher R. (1985).** Axenfeld-Rieger syndrome. A spectrum of developmental disorders. *Surv Ophthalmol*, 29, 387 - 409
- 10. Sowden J.C. (2007).** Molecular and developmental mechanisms of anterior segment dysgenesis. *Eye*, 21, 1310-1318
- 11. Waring G.O. 3rd, Rodrigues M.M., Laibson P.R. (1975).** Anterior chamber cleavage syndrome. A stepladder classification. *Surv Ophthalmol*, 20(1), 3 -27

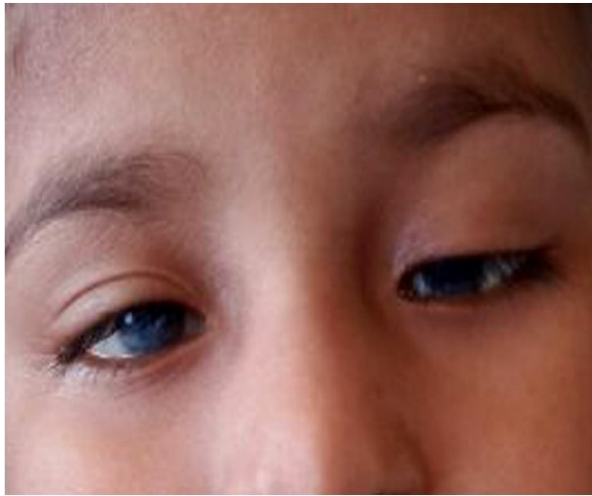

Figure 1: Microphthalmos, Microcornea, Strabismus, Corneal clouding

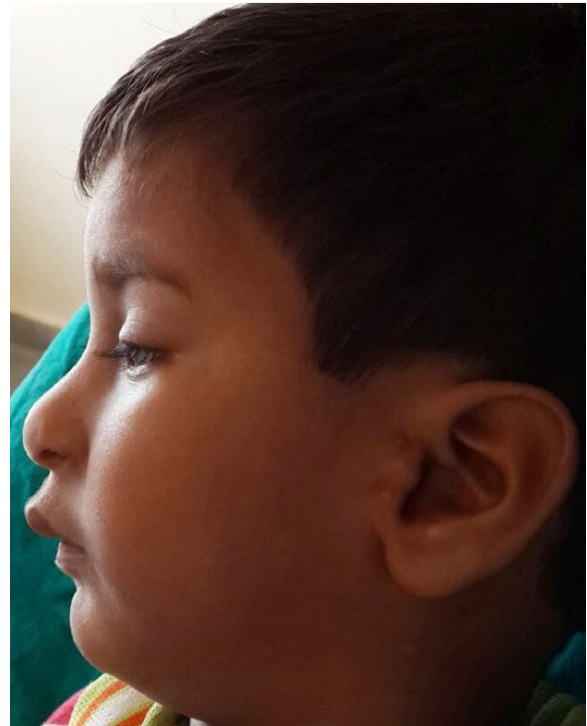

Figure 3: Beak shaped nose

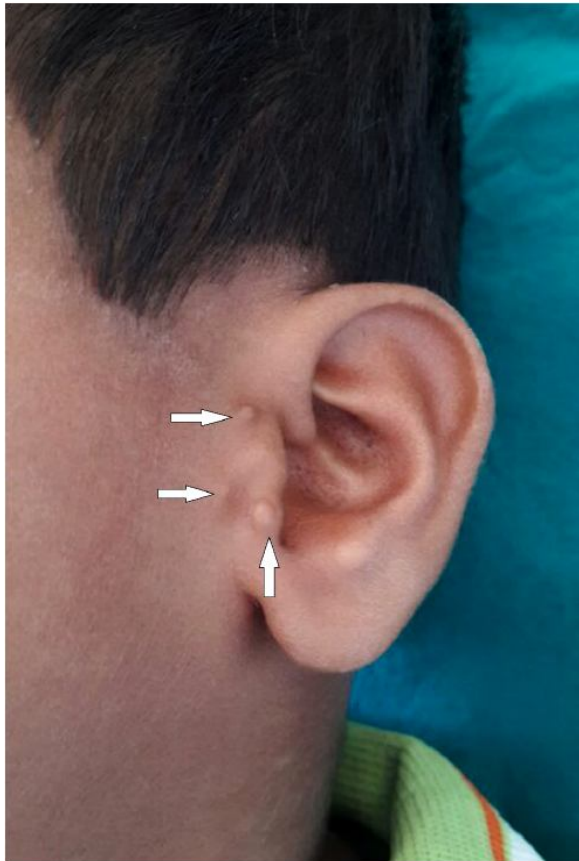


Figure 2: Preauricular Tags

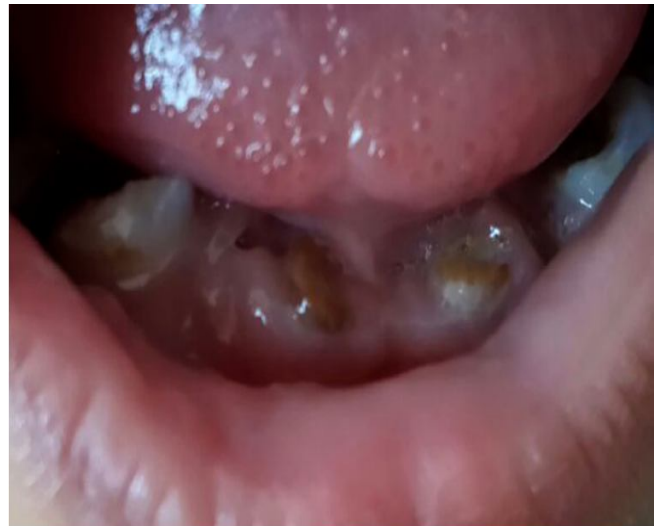

Figure 4: Missing 72, 73, 82, 83 and Ankyloglossia

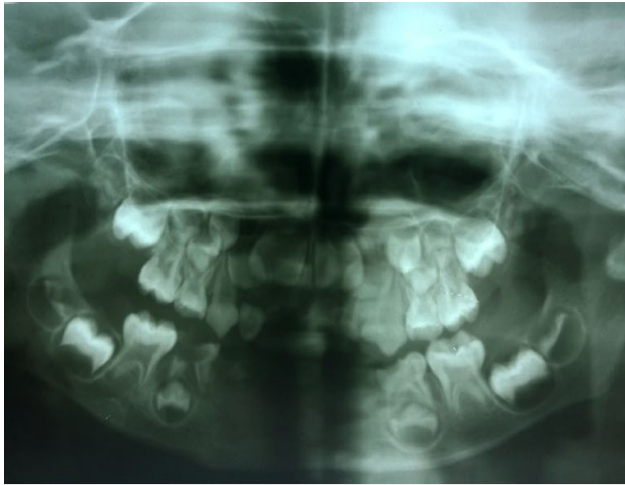

Figure 5: OPG showing absence of permanent lower anterior tooth buds

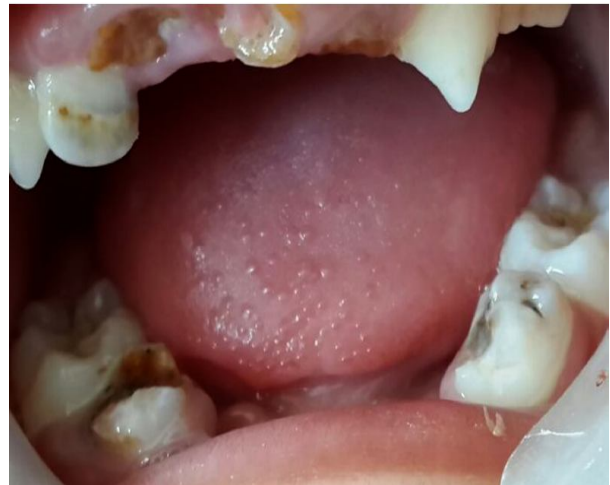

Figure 6: Multiple decayed teeth